

Possibilities of Prosthetic Implant Rehabilitation Using Various Materials for Bone Grafting

CALIN TATARU*, DORIANA AGOP FORNA, NORINA CONSUELA FORNA

Grigore T. Popa University of Medicine and Pharmacy, Faculty of Dental Medicine, 16 University Str., 700115, Iasi, Romania

Choosing the therapeutic implant prosthetic solution is the result of a careful analysis of the particularities of the prosthetic area, with a particular attention for the muco-bone support, for the presence of complications existent, locally or generally. The study looked for an individualization using different types of grafting materials in the therapeutic algorithm of implant-prosthetic rehabilitation methods. The study group included 98 patients in the private practice of dentistry in Baia Mare, and also those within the discipline of Prosthodontics and Oral Implantology of the Base Clinical Education of the Faculty of Dental Medicine Iasi, who were diagnosed with different types of edentation and who will benefit from reconstructive techniques based on different grafting systems. According to each specific clinical case there were used in implant prosthetic rehabilitation algorithm different types of bone grafting, 60% for using heterografts, 30% for allografts and autografts 10%. Regarding the possibilities of prosthetic implant rehabilitation, a percentage of 65% has been met for the different types of fixed restorations on implants and a 35% for removable prosthetic implants. 1. Out of the grafting materials used, xenografts are successful in different types of augmentations contributing to the success of implant treatment with thorough clinical and laboratory evaluation of the patient candidate for the implant and with the compliance of the rigorous surgical protocols.

Key words: regeneration, biomaterials, augmentation, prosthetic implant rehabilitation

There are natural bone substitutes obtained from the mineral part of the bovine bone, very similar to human bone. Generally, these substitutes of human bone exhibit a number of features similar to these, namely: their porosity is as high (equal to the natural bone) stimulating the blood vessels formation and bony cells migration to the augmentation material interconnecting the entire porous system; large internal surface (like in natural bone) allows intimate contact with the new bone tissue; the fine crystalline structure (like the natural bone) allows the bone remodelling process; chemically it is similar to the natural bone and leads to a high tissue compatibility (ratio Ca / P, Bio-Oss material, eg: 2.03; human bone: 2.03); slow resorption of the matrix structure: the bone grains applied protect the newly formed bone against resorption. The dimensional stability and zone volume of the augmented zone is kept [1,2].

Choosing the therapeutic implant prosthetic solution is the result of a careful analysis of the particularities of the prosthetic area, with a particular attention for the muco-bone support, for the presence of complications existent, locally or generally [3-5, 14]. This assessment of dento-periodontal support adjoining the area to be rehabilitated or at an antagonist and muco-bone level can be done using clinico-biological clues [6, 7].

Experimental part

The study looked for an individualization using different types of grafting materials in the therapeutic algorithm of implant-prosthetic rehabilitation methods. The study by clinical and laboratory methods of the peculiarities of the clinical case for implant candidate is an essential condition for targeted therapy, but also a starting point for a rigorous selection of the dental materials involved and requirements related to high fidelity morphology.

The study group included 98 patients in the private practice of dentistry in Baia Mare, and also those within the discipline of Prosthodontics and Oral Implantology of

the Base Clinical Education of the Faculty of Dental Medicine Iași, who were diagnosed with different types of edentation and who will benefit from reconstructive techniques based on different grafting systems.

Results and discussions

Subsequently the analysis of the quantified data, the following results were obtained

We notice a prevalence of females in the proportion of 58% compared to males at a rate of 42%.

Belonging to a particular gender influences the aesthetic requirements / functional or both of implant prosthetic solution chosen (fig. 1).

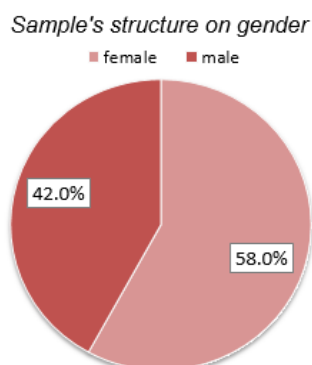


Fig. 1. Structure lot on sexes

Patients in the analyzed group were aged between 20 and 70 years, with a prevalence of 50-59 age range followed that share ranges 40-49 and 30-39 years (fig. 2).

General condition influences the complexity of implant-prosthetic rehabilitation maneuvers 35% of patients have a good general status, 20% have a general status affected by various forms of cardiovascular disease, 15% have diabetes and rheumatic 8% of patients in the study group shows liver disease and 7% kidney disease (fig. 3).

There is a considerable prevalence of Class I Kennedy 30%, followed by Class II Kennedy 18%, Class III Kennedy and subtotal edentation are found in 15%, Class IV Kennedy

* email: tataru.calin@yahoo.com; Phone: 0722282194

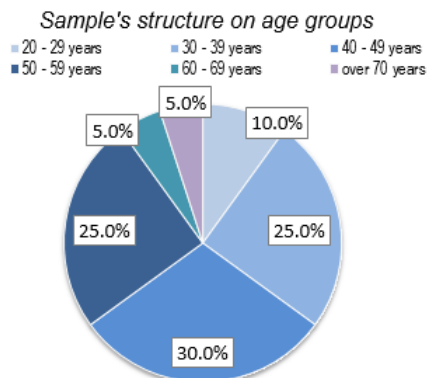


Fig. 2. Structure lot by age

The edentulous classes prevalence

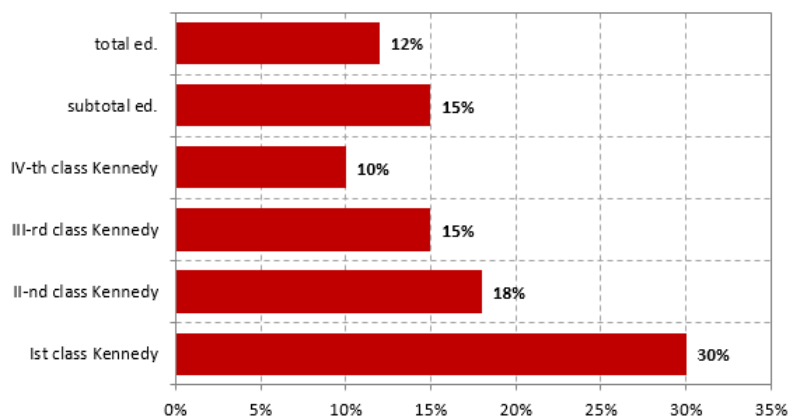


Fig. 4 The Prevalence of edentation classes

Sample's structure according to the general status

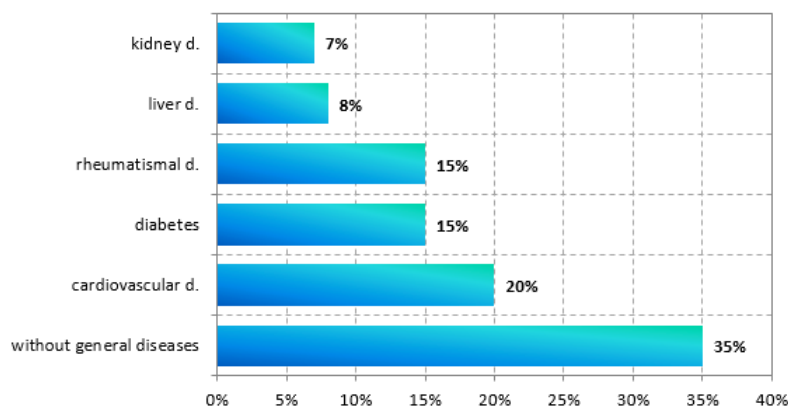


Fig. 3. Distribution of the batch in accordance with the general status

Possibilities of implant-prosthetic rehabilitation

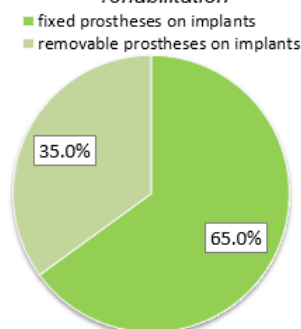


Fig. 5 Opportunities for implant-prosthetic rehabilitation

has a percentage of 10% and the total edentation 12% (fig. 4).

Surgical procedures on the edentulous unidentary spaces: Under local anesthesia, the lining is incised by a para-localized incision at about 2-3 mm from the midline to the palate and will be extended into sulcus of the adjacent teeth at the vestibular level. Incisions avoid scarring tissue formation at the midpoint for growth and vascularization flap, ensures sufficient vestibular papillae in the future [8, 9]. Vestibular angled incisions are the most used and allow a good approach to the bone. In patients requiring bone augmentation procedures, this type of flap would close without easing tensions with coronary periosteal flap and mobilization. As an alternative, the technique of parapapillary incision could be used [10, 11]. Implant placement without raising the flap (a technique called *flapless implant placement*) is considered experimental because there isn't insufficient evidence published in studies yet [12, 13].

Surgical procedures at the level of the extended edentulous spaces: At the implantation sites where several teeth are missing, the surgical technique is clearly more complicated and requires an optimal pre-operative plan. Using a surgical template is mandatory to determine correct positioning of implants in all 3 dimensions.

In sites with adjacent implants, it has to be considered another aspect, too: inter-implant distance. In such areas, the bone resorption of 1-2 mm at the proximal areas leads to flattening of inter-implant bone and automatically shorten inter-implant papillae. A distance of at least 3 mm is recommended to be kept between two adjacent implants to minimize bone resorption.

Regarding the possibilities of prosthetic implant rehabilitation, a percentage of 65% has been met for the

different types of fixed restorations on implants and a 35% for removable prosthetic implants (fig. 5).

According to each specific clinical case there were used in implant prosthetic rehabilitation algorithm different types of bone grafting, 60% for using heterografts, 30% for allografts and autografts 10% (fig. 6).

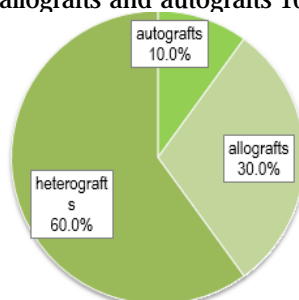


Fig. 6 Types of augmentation materials used

Autogenous bone remains the best augmentation material due to its osteogenic, allowing much faster the bone formation in cases where important defects are to be augmented (medium and large defects). Currently, autogenous bone is considered the only osteogenic material available for practitioners. In the past, the alveolar ridge augmentation was mainly based on allogeneic transplants or autologous bone. In cases of minor bone resorption, getting a corresponding bone bed is mainly combined with allogenous materials or membrans. The natural origin of the materials used as heterografts is the reason for a high osteoconductivity and their excellent osseointegration. Autografting techniques are generally not necessary. The amount of newly formed bone is significantly increased.

Heterografts successfully regenerate bone and provide a long-term survival rate of over 90% of the implants. Thus, the Bio-Oss material, for example, is identified by the body

as a natural bone structure. The material shows a large tissue compatibility and good osseointegration properties. The high rate of a long-term survival of the implants in areas with augmentation have been proven scientifically and repeatedly and has a survival rate similar to the conventional placed implants (fig.7).

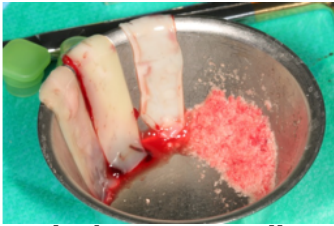


Fig. 7. Practical aspect of Bio-Oss and collagen membrane

The bone grains adhere in the bone defects: are strongly hydrophilic. The particles stick to each other and can easily be placed and shaped in the defect, provided that the particles are in close contact directly with the bone. Applying excessive pressure should be avoided so that it remains enough space for the growth of new bone. The small size of the beads/grains (0.25-1 mm), allowing intimate contact with the wall surrounding bone is recommended for smaller defects with up to two sockets for shaping autogenous block grafts. The large grains (1-2 mm) offer more space for bone cell growth. It is recommended for large augmentations, more than two sockets and for the augmentation of the sinus floor (fig.8).

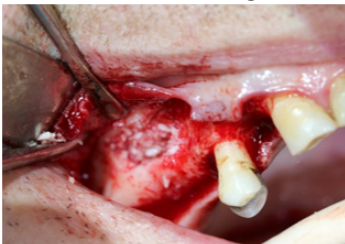


Fig.8 Practical aspect of augmentation of the sinus floor

Types of alveolar ridges

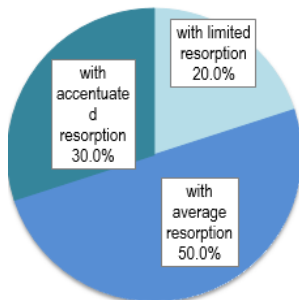


Fig. 9-Prosthetic implant rehabilitation using bone augmentation in different types of alveolar crest

Regeneration materials based on collagen foam is a mixture of granules with a supplement of 10% highly purified porcine collagen. Collagen supplement makes it very easy to cut into the desired shape and applied with forceps. However, collagen is not a functional barrier. Besides small implant defects, these types of materials are indicated, in particular, for postextractional and periodontal pockets.

Regarding the prevalence of ridge types, the predominant ridge with average resorption has a rate of 50%, followed by the sharp ridge resorption, 30% and the alveolar ridge limited resorption was present in 20% of cases (fig. 9).

Using xenografts demonstrated effectiveness in increasing the height and bone volume in cases of bone atrophy of the posterior maxillary region. Inorganic bovine bone matrix alone or in combination with autologous bone graft material is chosen by many practitioners in the sinus floor elevation. In fact in the literature, using xenografts as a grafting material is best documented.

In another paper was studied the effect of the collagen membranes in bone grafting for dental implants [15].

Conclusions

Out of the grafting materials used, xenografts are successful in different types of augmentations contributing to the success of implant treatment with thorough clinical and laboratory evaluation of the patient candidate for the implant and with the compliance of the rigorous surgical protocols.

Choosing the rehabilitation variant for the therapeutic implant is in full agreement with the particular clinical case with the graft systems used, the number of implants used.

The clinical and laboratory assessment materializes into an essential factor in choosing the grafting system in full agreement with the architecture of the prosthetic field.

References

1. BECKER, J., AL-NAWAS, B., KLEIN, M.O., SCHLIEPHAKE, H., TERHEYDEN, H., SCHWARZ, E.: Use of a new cross-linked collagen membrane for the treatment of dehiscence-type defects at titanium implants: a prospective, randomized-controlled double-blinded clinical multicenter study. *Clin Oral Implants Res*, **20**(3), 2007, pg.742.
2. BEITLITUM, I., ARTZI, Z., NEMCOVSKY, CE.: Clinical evaluation of particulate allogeneic with and without autogenous bone grafts and resorbable collagen membranes for bone augmentation of atrophic alveolar ridges. *Clin Oral Implants Res*, **21**(4), 2010, pg. 1242.
3. CALVO-GUIRADO, J.L., ORTIZ-RUIZ, A.J., NEGRI, B., LÓPEZ-MARÍ, L., RODRIGUEZ-BARBA, C., SCHLOTTIG, F.: Histological and histomorphometric evaluation of immediate implant placement on a dog model with a new implant surface treatment. *Clin Oral Implants Res*, **21**, 2010,pg. 308.
4. CHETRUS, V.,ROMAN, L.:Gingival recession, Diagnostic methods, *Romanian J.of Oral Rehab.*, **(6)**3, 2014, pg.38
5. BARTOK, F.F., FORNA, N.C., *Rev. Chim. (Bucharest)*, **67**, no. 9, 2016, p. 1722
6. CHIAPASCO, M., ZANIBONI, M.: Clinical outcomes of GBR procedures to correct peri-implant dehiscences and fenestrations: a systematic review. *Clin Oral Implants Res*, **20**(4), 2009, pg.113.
7. FRIEDMANN, A., GISSEL, K., SOUDAN, M., KLEBER, B.M., PITARU, S., DIETRICH, T., Randomized controlled trial on lateral augmentation using two collagen membranes: morphometric results on mineralized tissue compound. *J Clin Periodontol*, **38**, 2011pg.677.
8. JENSEN, SS., TERHEYDEN, H.: Bone augmentation procedures in localized defects in the alveolar ridge: clinical results with different bone grafts and bone-substitute materials. *Int J Oral Maxillofac Implants*, **24**(2), 2009, pg.218.
9. JUNG, RE., HÄLG, GA., THOMA, DS., HÄMMERLE, CH.: A randomized, controlled clinical trial to evaluate a new membrane for guided bone regeneration around dental implants. *Clin Oral Implants Res*, **20**(2), 2009, pg.162.
10. MALONEY, WJ., WEINBERG, MA.: Implementation of the American Society of Anesthesiologists Physical Status classification system in periodontal practice. *J Periodontol*, **79**(2), 2008, pg.1124.
11. MERLI, M., LOMBARDINI, F., ESPOSITO, M.: Vertical ridge augmentation with autogenous bone grafts 3 years after loading: resorbable barriers versus titanium-reinforced barriers. A randomized controlled clinical trial. *Int J Oral Maxillofac Implants*, **25**(1), 2010, pg.801.
12. SCHWARZ, F., SAGER, M., KADELKA, I., FERRARI, D., BECKER, J.: Influence of titanium implant surface characteristics on bone regeneration in dehiscence-type defects: an experimental study in dogs. *J Clin Periodontol*, **37**, 2010, pg.466;
13. SCHWARZ, F., HERTEN, M., FERRARI, D., et al.: Guided bone regeneration at dehiscence-type defects using biphasic hydroxyapatite + beta tricalcium phosphate (Bone Ceramic) or a collagen-coated natural bone mineral (Bio-Oss Collagen): an immunohistochemical study in dogs. *Int J Oral Maxillofac Surg*, **36**(7), 2007, pg.1198
14. HOLBAN CIOLOCA, C.M., AGOP FORNA, D., FORNA, N.C., *Rev. Chim. (Bucharest)*, **67**, no. 10, 2016, p. 2115